

Suspected Foreign Body Inhalation in Children: What Are the Indications for Bronchoscopy?

Shlomo Cohen, MD, Avraham Avital, MD, Simon Godfrey, MD, FRCP, Menachem Gross, MD, Eitan Kerem, MD, and Chaim Springer, MD

Objective To define the criteria for bronchoscopy in children with suspected foreign body (FB) inhalation.

Study design Health history, physical examination, and radiologic examination were performed before bronchoscopy in all children referred for suspected FB inhalation between 2003 and 2005.

Results A total of 142 children, ranging in age from 3 months to 14 years (median age, 20 months), were referred with a history of suspected FB inhalation. An FB was found in 42 children with abnormal physical and radiologic findings, in 17 children with abnormal physical or radiologic findings, and in 2 children with normal physical and radiologic finding but persistent cough. Bronchoscopy revealed no FB in the children with normal physical and radiologic examinations and no symptoms (n = 16).

Conclusion In children with a history of choking, bronchoscopy is mandatory in the presence of persistent symptoms, such as cough, dyspnea, and fever, or any abnormal physical or chest radiography findings. Bronchoscopy is not necessary in asymptomatic children with normal physical and radiographic examinations. (*J Pediatr* 2009; ■: ■-■).

Foreign body (FB) inhalation in children is a dangerous event. It is the most common cause of accidental death in children under age 1 year,¹ and the risk for FB inhalation remains very high up to age 3 years. The majority of inhaled FBs are food items, predominantly seeds and dried fruits.²⁻⁴ Prevention and rapid diagnosis can be lifesaving.⁵⁻⁷ The clinical presentation and radiologic findings may be variable, can change with time, can be interpreted differently by different examiners, or may even be normal.⁸⁻¹¹ Inhalation of an FB into the airways is usually a dramatic event that can result in sudden suffocation, choking, and paroxysms of coughing, followed by tachypnea and dyspnea. After the acute event, the effects may change, ranging from minimal to signs and symptoms of complete airway obstruction.

The indications for bronchoscopy in cases of suspected FB inhalation are not well defined. Usually, a clear history of sudden suffocation, a choking event combined with abnormal chest examination, or radiologic findings are accepted as reliable criteria justifying the performance of bronchoscopy. A dilemma arises when a child with a suspected inhalation event presents with a normal physical examination or a normal chest radiograph. In our institution, there once was no unified approach for determining when to perform bronchoscopy in such cases. Most children were referred for bronchoscopy based on a positive history only; however, some physicians required at least an abnormal physical or radiologic examination. To develop reliable criteria for bronchoscopy, we conducted a prospective 3-year study during which all children who presented to our emergency room (ER) with a history of suspected FB inhalation underwent bronchoscopy. The results of the bronchoscopy were analyzed according to the initial ER assessment.

Methods

Between 2003 and 2005, all children age 3 months to 14 years who presented to the ER of the Hadassah University Hospitals with a suggestive history of suspected FB inhalation within the past month were referred for bronchoscopy (n = 142). A suggestive history included either a witnessed report of an acute episode of choking (n = 106) or an acute persistent cough (n = 36).

Before bronchoscopy, each child was examined by an experienced team comprising a pediatrician, a pediatric pulmonologist, and/or an otolaryngologist, who reevaluated the history, symptoms, physical, and radiologic findings. Symptoms included cough, dyspnea, labored breathing, drooling, dysphagia, vomiting, and fever. Abnormal physical findings included cough, fever, tachypnea, hypoxemia, decreased lung sounds, wheezes, and crackles. Abnormal radiologic findings included air-trapping, atelectasis, infiltration, mediastinal shift, and radioopaque FB.

ENT	Ear, nose, and throat
ER	Emergency room
FB	Foreign body

From the Institute of Pulmonology (S.C., A.A., S.G., C.S.), ENT Department (M.G.), Hadassah Ein Kerem, and Pediatric Department (E.K.), Hadassah Mount Scopus, Hadassah-Hebrew University Medical Centers, Jerusalem, Israel

The authors declare no potential conflicts of interest, real or perceived.

0022-3476/\$ - see front matter. Copyright © 2009 Mosby Inc. All rights reserved. 10.1016/j.jpeds.2009.02.040

All 142 children were assigned before bronchoscopy to 1 of 5 groups according to symptoms and physical and radiographic findings: (1) children with abnormal physical and radiologic findings ($n = 63$), (2) children with abnormal physical findings and normal radiologic findings ($n = 22$), (3) children with normal physical findings and abnormal radiologic findings ($n = 10$), (4) children with normal physical and radiologic findings but with symptoms ($n = 31$), and (5) children with normal physical and radiologic findings and no symptoms ($n = 16$).

Bronchoscopy was performed in all children within 24 hours of hospitalization. Written informed consent to perform bronchoscopy was provided by all parents before the procedure.

Flexible or rigid bronchoscopy was performed after 6 hours of fasting, under general anesthesia with sevoflurane gas or intravenous propofol. All of the bronchoscopies were performed by experienced physicians, either ear, nose, and throat (ENT) surgeons or pediatric pulmonologists. Our institution is unusual in that both the ENT surgeons and the pediatric pulmonologists are experienced in performing rigid bronchoscopy, whereas only the pediatric pulmonologists perform flexible bronchoscopy. Children with abnormal physical and radiologic findings are usually referred and treated by the ENT surgeons unless an ENT surgeon or an operating room is unavailable. All other children are referred to the pediatric pulmonologists, who perform flexible bronchoscopy as the first procedure and continue with rigid bronchoscopy (under the same anesthesia) when an FB is found.

All children were observed in the hospital for 6 to 24 hours after the procedure for immediate complications and over the subsequent month for late complications.

Statistical Analysis

Two-sided Fisher exact tests were used to compare results and calculate sensitivity, specificity, and positive and negative predictive values of each variable. P values $< .05$ were considered significant.

Results

An FB was found in the airway in 61 of the 142 children (43%). In all of these children, the FB was completely removed. The mean age of the children who inhaled an FB was 2.8 years (range, 3 months to 14 years; median, 19.5 months); 75% were under age 3 years, and 62% ($n = 38$) were boys. Most of the inhaled FBs were seeds or dried fruits (67%). Of the 61 FBs found, 5 were radioopaque and 4 were found in children over age 5 years (scarf pins in Muslim girls). Of the 61 children with an inhaled FB, 42 (69%) were of Arab origin and 19 (31%) were Jewish. Some 87% of the inhaled FB events occurred at home. Of the 106 children with a history of choking, only 51 (48%) had an FB detected by bronchoscopy.

The incidence of FB inhalation confirmed by bronchoscopy was analyzed by the presence or absence of clinical and radiological findings (Figure 1). The primary symptom

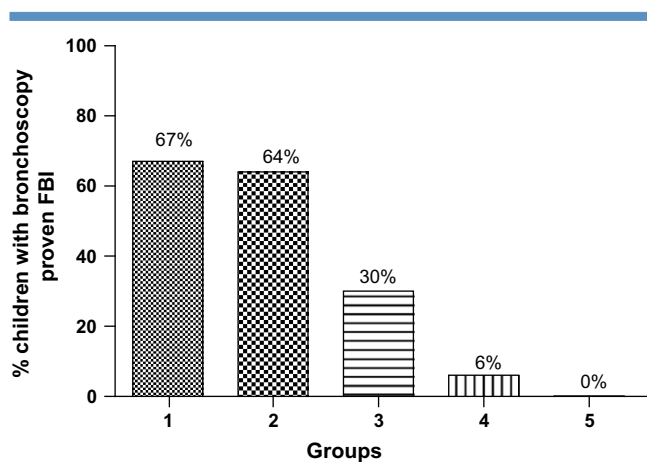


Figure 1. Incidence of FB inhalation found on bronchoscopy. Group categorizations: Group 1, children with abnormal physical and radiologic findings ($n = 63$); group 2, children with abnormal physical and normal radiologic findings ($n = 22$); group 3, children with normal physical and abnormal radiologic findings ($n = 10$); group 4, children with normal physical and radiologic examination with symptoms ($n = 31$); group 5, children with normal physical and radiologic examination and no symptoms ($n = 16$).

after the acute event was cough ($n = 115$; 81%), but fever ($n = 34$), oxygen desaturation ($n = 11$), labored breathing ($n = 2$), drooling ($n = 1$), and dysphagia ($n = 1$) also were observed.

Clinical Findings

Localized areas of decreased lung sounds and wheezes were significantly more common in the children with FB inhalation compared with the children with normal bronchoscopy findings (decreased lung sounds, 57% vs 15%; wheezes, 43% vs 17%). There were no significant differences in the prevalence of crackles, signs and symptoms of upper respiratory tract infection, or history of asthma between the 2 groups (Table).

Chest Radiographic Findings

Mediastinal shift and radioopaque FBs were found only in the children with an inhaled FB. Localized air-trapping was significantly more common in the children with an inhaled FB (50% vs 14%) (Table).

Of the 61 children with a bronchoscopy-proven FB inhalation, 4 (7%) had normal chest auscultation, 16 (26%) had normal chest radiographs, and 2 (3%) had both normal chest auscultation and normal chest radiographs. However, it should be emphasized that these 2 children suffered from persistent cough, which began immediately after the suspected inhalation event.

There was no clinical or radiologic finding with a sufficiently high sensitivity and specificity or positive or negative predictive value that could reliably differentiate between the children with or without FB inhalation (Table).

Table. Clinical and radiologic findings in the 142 children with suspected FB aspiration

	FB found (n = 61), % (n)	FB not found (n = 81), % (n)	Sensitivity	Specificity	PPV	NPV	P
History: Witnessed choking event	84% (51)	68% (55)	0.92	0.32	0.50	0.84	.0008
Symptoms: Cough	92% (57)	72% (58)	0.92	0.28	0.49	0.82	.003
Physical examination							
Fever > 37.8 °C	31% (19)	43% (35)					NS
SaO ₂ < 94%	15% (9)	2% (2)	0.25	0.97	0.88	0.63	<.0001
Dyspnea/tachypnea	15% (9)	7% (6)					NS
Localized decreased lung sounds	57% (35)	15% (12)	0.57	0.85	0.74	0.73	<.0001
Localized wheeze	43% (26)	17% (14)	0.43	0.83	0.65	0.66	.001
Localized crackles	25% (15)	14% (11)					NS
Normal auscultation	7% (4)	65% (53)	0.07	0.35	0.07	0.33	<.0001
History of asthma	10% (6)	9% (7)					NS
Upper respiratory tract infection	26% (16)	36% (29)					NS
Chest radiographs							
Localized air-trapping	50% (30)	14% (11)	0.51	0.86	0.74	0.70	.001
Localized atelectasis	7% (4)	4% (3)					NS
Localized infiltrate	15% (9)	21% (17)					NS
Mediastinal shift	13% (8)	0	0.13	1.00	1.00	0.60	.001
Radioopaque FB	10% (6)	0	0.10	1.00	1.00	0.60	.01
Normal	26% (16)	67% (54)	0.26	0.33	0.23	0.36	<.0001

NPV, negative predictive value; NS, not significant; PPV, positive predictive value; SaO₂, oxygen saturation.

Bronchoscopy Findings

The mean time from the suspected inhalation event to bronchoscopy was 93 hours (range, 3 hours to 30 days; median, 48 hours). Some 90% of the FBs found were removed during rigid bronchoscopy. In 6 children (10%), the FB was removed during flexible bronchoscopy using a Pentax 15 bronchoscope and alligator forceps. Most of the inhaled FBs were seeds or dried fruits (67%). In terms of location, 46% of the FBs were found in the left-side airways, 37% were found in the right-side airways, 15% were found in the trachea, and 2% were found in the larynx.

An FB was found in all 6 children with a radioopaque foreign body, in all 8 children with a mediastinal shift, and in 23 of 28 children (82%) with unilateral wheezes or decreased lung sounds combined with unilateral hyperinflation or atelectasis (Table).

Minor complications after bronchoscopy (eg, mild temporary hypoxia, fever within 24 hours) were noted in 12 children, 10 of whom had undergone rigid bronchoscopy. One immediate major complication developed during rigid bronchoscopy in a child with an FB that was blocking the trachea. This child had transient severe hypoxemia and bradycardia that resolved after the FB was removed.

Discussion

In children with a suggestive history of FB inhalation, bronchoscopy is mandatory in those with abnormal physical and/or radiologic findings, and also in those with symptoms (eg, cough, fever, dyspnea, dysphagia) but no physical or radiologic abnormalities. In our study group, we did not detect an FB in any of the asymptomatic children with normal physical and radiologic findings. Thus, we believe that these children do not require immediate bronchoscopy; rather, they can be followed and treated according to their clinical status (Figure 2).

The accurate diagnosis of FB inhalation cannot rely on history alone even if based on a witnessed choking event. Although such a history was obtained in 84% of the children with a proven FB inhalation, it also was obtained in 68% of the children without FB inhalation (sensitivity, 0.92; specificity, 0.32; Table). An FB was not detected in 52% of the children with a witnessed choking event.

Although numerous published retrospective studies address the role of symptoms, signs, and radiography in the diagnosis of children with suspected FB inhalation, only a few prospective studies have been published to date.¹²⁻¹⁵ Righini et al¹³ reported a prospective study of 70 children with suspected FB inhalation. An inhaled FB was found in 50 of these children (71%), 7 of whom had normal physical and radiologic examinations. However, 5 of these children had a refractory cough, and 2 had cough and fever.

In our study group, of the 61 children with bronchoscopy-proven FB inhalation, 7% had normal chest auscultation, 26% had normal chest radiographs, and 3% (2 children) had both normal chest auscultation and chest radiographs (Table). Note, however, that these latter 2 children were symptomatic and exhibited persistent coughing starting immediately after the suspected inhalation event.

The prevalences of a previous history of asthma and clinical signs and symptoms of upper respiratory tract infection were not significantly different in the children with FB inhalation and those without FB inhalation. Thus, such a history should not influence the decision of whether or not to perform bronchoscopy.

The rate of positive bronchoscopies in our study was 43% of all children. Excluding the 16 asymptomatic children from the analysis, as we recommend, would increase the rate of positive bronchoscopies to 48%. In the literature, the rate of positive bronchoscopies ranges from 25% to 90%^{7,16-18} and depends mainly on the strictness of the indications for performing bronchoscopy.

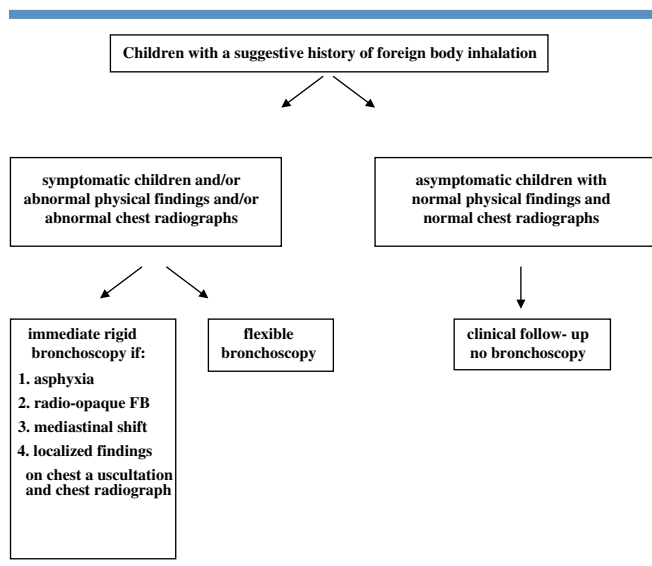


Figure 2. A recommended decision tree for FB aspiration in children.

In most centers, patients with suspected FB inhalation are treated by ENT surgeons, who generally perform rigid bronchoscopy because of their training and experience. In some centers, the children are first evaluated by pediatric pulmonologists, who generally are familiar only with flexible bronchoscopy. We believe that bronchoscopy for suspected FB inhalation should be performed by a team of physicians (pediatric pulmonologists and ENT surgeons) well experienced in both types of procedures. How should such a team determine the appropriate procedure? Wood and Gauderer¹⁹ and the American Thoracic Society²⁰ recommend that flexible bronchoscopy should be the first procedure in cases of equivocal FB inhalation, to avoid unnecessary rigid bronchoscopies. In view of our findings, we recommend that rigid bronchoscopy be performed as the first procedure in children with one of the following: a radioopaque FB, a mediastinal shift, or localized wheezing or decreased lung sounds combined with unilateral atelectasis or hyperinflation. Another indication for immediate rigid bronchoscopy (although not observed in our study) is to treat an asphyxiating child with a history of suspected FB inhalation. In all other cases, flexible bronchoscopy should be done first, continuing with rigid bronchoscopy as needed under the same anesthesia. These procedures can be done either in a bronchoscopy suite or in the operating room which are appropriately equipped with all the necessary facilities and thus avoid an unnecessary second anesthesia. This approach has been adopted and the setup exists in our institution. It should be emphasized that the second best and legitimate approach is a 2 stage procedure: a flexible diagnostic bronchoscopy followed by a rigid bronchoscopy in the operating room when needed.

Recently, several articles have been published addressing the usefulness of flexible bronchoscopy in extracting inhaled FBs in children. Swanson et al²¹ reported that in 26 of 39 chil-

dren, the inhaled FB could be extracted with a flexible bronchoscope. This was done through an endotracheal tube, a laryngeal mask airway, or a rigid bronchoscope. The FBs were grasped with urologic forceps or a basket. Ramirez-Figueroa et al²² reported extracting an FB in 21 of 22 children using a flexible bronchoscope. In our study, it was possible to extract the FB during flexible bronchoscopy in 6 of the 61 children. These children had aspirated dry seeds or other flat FBs that could be easily grasped and extracted with the alligator biopsy forceps of the flexible bronchoscope. Extracting soft FBs, such as peanuts, is more difficult with such forceps, because these FBs are usually crushed and fragmented into small pieces. It should be emphasized that such a procedure must be performed through the mouth or using a laryngeal mask airway,²³ to prevent the FB from becoming stuck in the nasal passages. We agree with the conclusion of Swanson et al²¹ that a rigid bronchoscope should be readily available when FB extraction is being attempted using a flexible bronchoscope.

In our study, 46% of the FBs were found in the left-side airways and 37% were found in the right-side airways. In most previous studies, FB were found predominately in the right-side airways;^{21,22} however, Sameh et al²⁴ reported findings 58% of inhaled FBs in the left-side airways.

The nature and rate of the FBs found differed in the 2 groups in our study. The rate of FB detection by bronchoscopy was 56% in the Arab children, compared with only 28% in the Jewish children. Given that Arabs comprise about 1/3 and Jews comprise almost 2/3 of the total population in Jerusalem, the risk of FB inhalation is 4 times higher in the Arab children. Similar findings were reported by Even et al.¹⁴ The high rate of FB inhalation in Arab children can be attributed to the fact that eating seeds and dried fruits is a widespread custom in this population. The inhaled FBs were dried fruits in 76% of the cases in Arab children, compared with 52% in Jewish children ($P = .08$). Five of the 61 FBs found were radioopaque, and 4 of these FBs were found in children over 5 years old (scarf pins in Muslim girls).

The main goal in treating FB inhalation in children is prevention.²⁵ This should be facilitated by educating parents of young children to avoid keeping seeds and dried fruits in the home. ■

Submitted for publication Aug 27, 2008; last revision received Dec 16, 2008; accepted Feb 24, 2009.

Reprint requests: Chaim Springer, MD, Institute of Pulmonology, Hadassah University Hospital, POB 12000, Jerusalem 91120, Israel. E-mail: chaim.springer@gmail.com.

References

1. Mofenson HC, Greensher J. Management of the choking child. *Pediatr Clin North Am* 1985;32:183-92.
2. Cohen SR. Unusual presentations and problems created by mismanagement of foreign bodies in the aerodigestive tract of the pediatric patient. *Ann Otol Rhinol Laryngol* 1981;90:316-22.
3. Mantel K, Butenandt I. Tracheobronchial foreign body aspiration in childhood: a report on 224 cases. *Eur J Pediatr* 1986;45:211-6.

4. Banerjee A, Rao KS, Khanna SK, Narayanan PS, Gupta BK, Sekar JC, et al. Laryngo-tracheo-bronchial foreign bodies in children. *J Laryngol Otol* 1988;102:1029-32.
5. Mu L, He P, Sun D. The causes and complications of late diagnosis of foreign body aspiration in children: report of 210 cases. *Arch Otolaryngol Head Neck Surg* 1991;117:876-9.
6. Karakoc F, Karadag B, Akbenlioglu C, Ersu R, Yildizeli B, Yukseln M, et al. Foreign body aspiration: what is the outcome? *Pediatr Pulmonol* 2002;34:30-6.
7. Schmidt H, Manegold BC. Foreign body aspiration in children. *Surg Endosc* 2000;14:644-8.
8. Laks Y, Barzilay Z. Foreign body aspiration in childhood. *Pediatr Emerg Care* 1988;4:102-6.
9. Losek JD. Diagnostic difficulties of foreign body aspiration in children. *Am J Emerg Med* 1990;8:348-50.
10. Svedstrom E, Puhakka H, Kero P. How accurate is chest radiography in the diagnosis of tracheobronchial foreign bodies in children? *Pediatr Radiol* 1989;19:520-2.
11. Skoulakis CE, Doxas PG, Papadakis CE, Proimos E, Christodoulou P, Bizakis JG, et al. Bronchoscopy for foreign body removal in children: a review and analysis of 210 cases. *Int J Pediatr Otorhinolaryngol* 2000;53:143-8.
12. Martinot A, Closset M, Marquette CH, Hue V, Deschildre A, Ramon P, et al. Indications for flexible versus rigid bronchoscopy in children with suspected foreign-body aspiration. *Am J Respir Crit Care Med* 1997;155:1676-9.
13. Righini CA, Morel N, Karkas A, Reyt E, Ferretti K, Pin I, et al. What is the diagnostic value of flexible bronchoscopy in the initial investigation of children with suspected foreign body aspiration? *Int J Pediatr Otorhinolaryngol* 2007;71:1383-90.
14. Even L, Heno N, Talmon Y, Samet E, Zonis Z, Kugelman A. Diagnostic evaluation of foreign body aspiration in children: a prospective study. *J Pediatr Surg* 2005;40:1122-7.
15. Ayed AK, Jafar AM, Owayed A. Foreign body aspiration in children: diagnosis and treatment. *Pediatr Surg Int* 2003;19:485-8.
16. Black RE, Johnson DG, Matlak ME. Bronchoscopic removal of aspirated foreign bodies in children. *J Pediatr Surg* 1994;29:682-4.
17. Emir H, Tekant G, Besik C, Elicevik M, Senyuz OF, Buyukunal C, et al. Bronchoscopic removal of tracheobronchial foreign bodies: value of patient history and timing. *Pediatr Surg Int* 2001;17:85-7.
18. Zrella JT, Dimler M, McGill LC, Pippus KJ. Foreign body aspiration in children: value of radiography and complications of bronchoscopy. *J Pediatr Surg* 1998;33:1651-4.
19. Wood RE, Gauderer MW. Flexible fiberoptic bronchoscopy in the management of tracheobronchial foreign bodies in children: the value of a combined approach with open tube bronchoscopy. *J Pediatr Surg* 1984;19:693-8.
20. Green CG, Eisenberg J, Leong A, Nathanson I, Schnapf BM, Wood RE. Flexible endoscopy of the pediatric airway. *Am Rev Respir Dis* 1992;145:233-5.
21. Swanson KL, Prakash UB, Midthun DE, Edell ES, Utz JP, McDoudall JC, et al. Flexible bronchoscopic management of airway foreign bodies in children. *Chest* 2002;121:1695-700.
22. Ramirez-Figueroa JL, Gochicoa-Rangel LG, Ramirez-San Juan DH, Vargas MH. Foreign body removal by flexible fiberoptic bronchoscopy in infants and children. *Pediatr Pulmonol* 2005;40:392-7.
23. Avital A, Gozal D, Uwyed K, Springer C. Retrieval of aspirated foreign bodies in children using a flexible bronchoscope and a laryngeal mask airway. *J Bronchol* 2002;9:6-9.
24. Sameh I, Walid H, Maha B, Mohammed M, Tarik ED, Abudlla E, et al. Inhaled foreign bodies: presentation, management and value of history and plain chest radiography in delayed presentation. *Otolaryngol Head Neck Surg* 2006;134:92-9.
25. Karatzanis A, Vardouiotis J, Moschandreass E, Prokopakis E, Papadakis D, Kyrmizakis J, et al. The risk of foreign body aspiration in children can be reduced with proper education of the general population. *Int J Pediatr Otorhinolaryngol* 2007;71:311-5.